

HAND TRAUMA

Hand trauma is similar with other trauma, but has also specific elements of evaluation and treatment.

PRIMARY EXAMINATION

Correct diagnosis and treatment of hand lesions begin with the clinical examination, considering the anatomical and functional relationships.

ANAMNESIS

It is important to know patients medical record, including allergies, immunizations (especially for tetanus), systemic disease, current medication, other surgeries.

The mechanism of injury and the position of the hand will also be investigated. Hand function before the accident will be questioned. Profession and hobbies will be also considered when therapeutical alternatives are discussed.

CLINICAL EXAMINATION

The most important aspect in hand examination is the viability of the segment distal to the trauma level. It is necessary to evaluate the color, witch has to be pink, the temperature of the distal segment, the capillary pulse, by nail bed compression and watching the time of recalibration and the turgor of the finger pulp.

Pale or white color, cold temperature of the skin, absence of the capillary pulse and persistent turgor are significant for major arterial lesions and devitalisation of the segment distal to the trauma level. Blue color, rapid capillary pulse and edema of the finger pulp are significant for major venous lesion and can also question the distal segment viability.

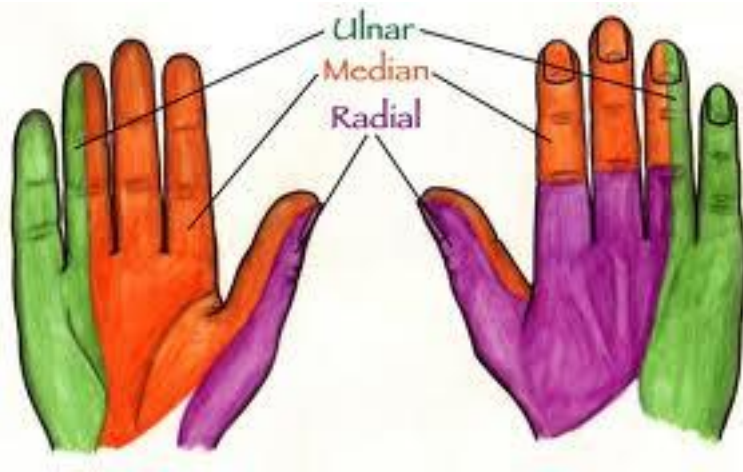Bone and joint lesions will be evaluated by radiological examination, usually in two incidences, antero-posterior and 45°.

Tendon lesions will determine the impossibility of movement of the phalanx where the tendon is inserted – FDP (flexor digiti profundus) tendon lesion will determine impossibility of distal phalanx movement, FDS (flexor digiti superficialis) tendon lesions will determine impossibility of middle phalanx movement, when the distal phalanx is in extension, extensor tendon lesions will determine impossibility of digit extension, but, because of the transverse connections of the extensor tendons on the dorsum of the hand, these lesions can be diagnosed sometimes only in wound exploration under anesthesia.

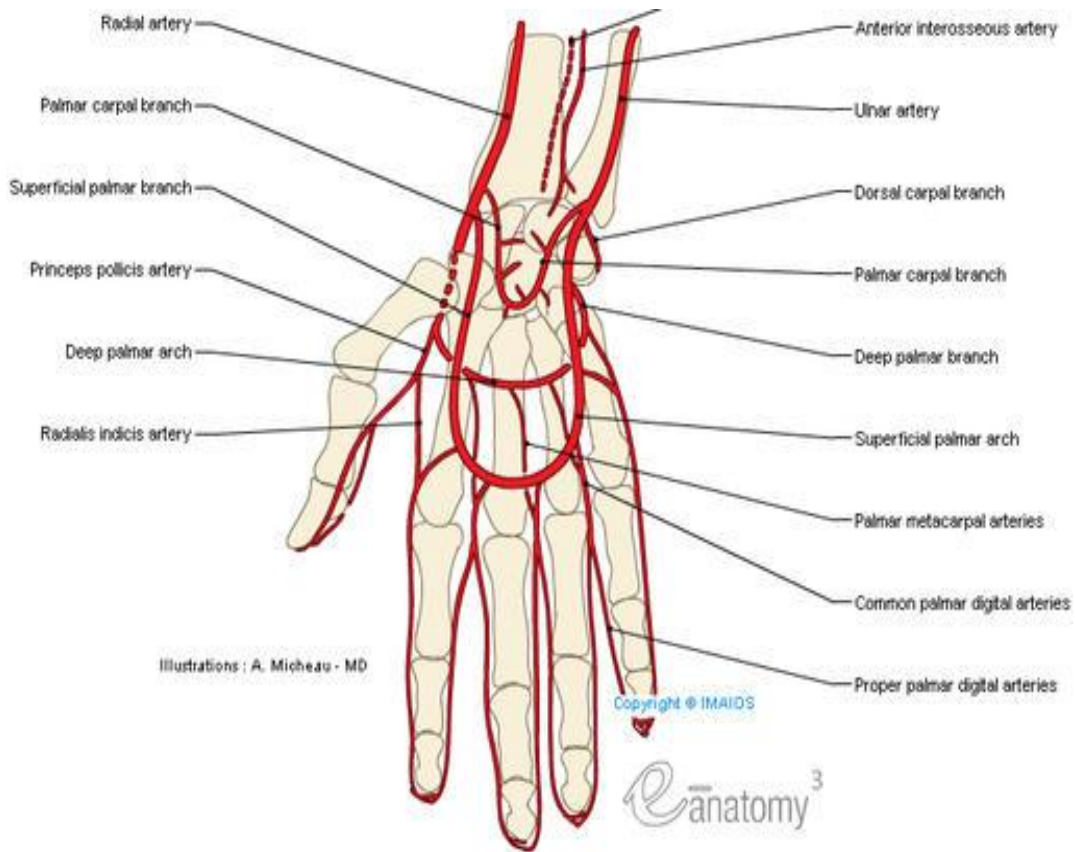
The nerve lesions determine anesthesia in the nerve's cutaneous territory and impossibility of the movements of the muscles innervated by this nerve. So, in median nerve lesions we will find anesthesia in the palmar side of the thumb, index, middle and external (radial) side of the ring finger and impossibility of thumb opposition. Ulnar nerve lesion will determine anesthesia in palmar side of little and internal (ulnar) side of the ring finger, impossibility of the abduction-adduction movements of the fingers and impossibility of flexion in MP (metacarpo-phalangeal) joints with IP (interphalangeal) joints in extension (performed by interosseous muscles). Radial nerve injury will determine anesthesia in the dorsal side of the hand and thumb, index, middle and external (radial) side of the ring finger until the middle phalanges.

RADIOLOGICAL EVALUATION

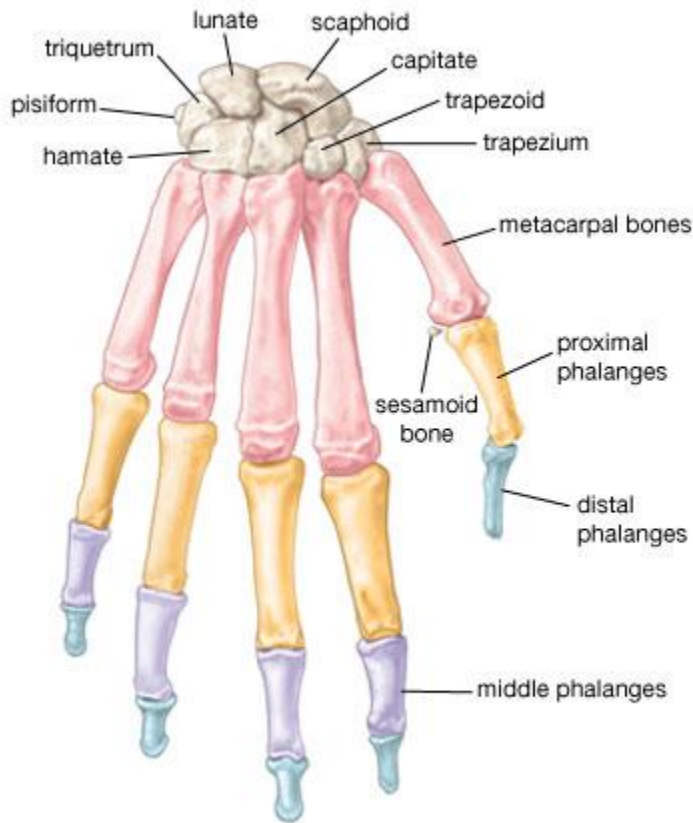
X-ray examination is very important in diagnosis and treatment planning. Standard two planes (anteroposterior and 45°) examination, including the wrist and the distal phalanges, is usually enough. Sometimes special incidences or even CT scan can be necessary.



1. Distribution of innervation



2. Arterial blood supply



© 2007 Encyclopædia Britannica, Inc.

3. Bones of the hand

TREATMENT

The function of the hand is the main topic of the treatment.

Minor contusions and sometimes simple fractures can be treated in the emergency room. Complex injuries will be treated only in the operating room, under adequate anesthesia.

There is necessary to use finger tourniquet (made by glove finger) or brachial tourniquet at systolic tension add 100mmHg pressure which will provide an exsanguine operating field for 1.5-2 hours maximum. Hand surgeons usually use magnification – 2-4.5x magnification loupes or even surgical microscope (for vessels and nerves repair). Bipolar acuter is also necessary for hemostasis.

The surgical steps in hand trauma are: washing of the wound with saline and sometimes antiseptic solution (betadine), taking out all foreign bodies, marginal excision of the devitalized tissue and

final lesions diagnosis and if necessary, bone fixation, extensor tendons and flexor tendons repair, vessels and nerves suture, skin repair to cover the „noble” structures .

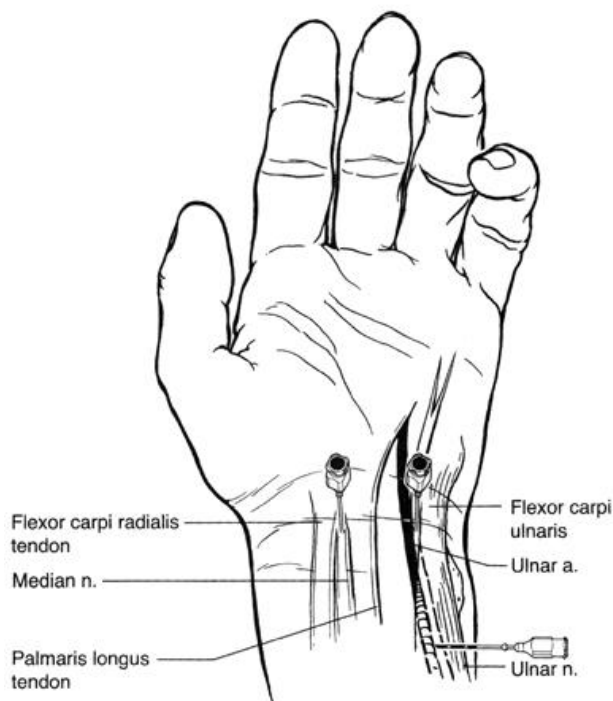
Immobilization of the hand in functional position (30-45⁰ extension of the wrist, 45-60⁰ flexion of the MP joints, 20-30⁰ flexion of the IP joints, and thumb in opposition) is necessary to avoid edema and pain.

ANESTHESIA

Almost all hand lesions can be treated under local or regional anesthesia. Patients with bone or tendon lesions may need muscle relaxation.

The most used regional anesthesia is axillary block, but can also be used intravenous regional anesthesia or troncular regional anesthesia (by infiltrating each nerve with the anesthetic solution).

Children and patients with bilateral hand lesions will need general anesthesia (IV, laryngeal mask or even intubation).



4. Wrist block

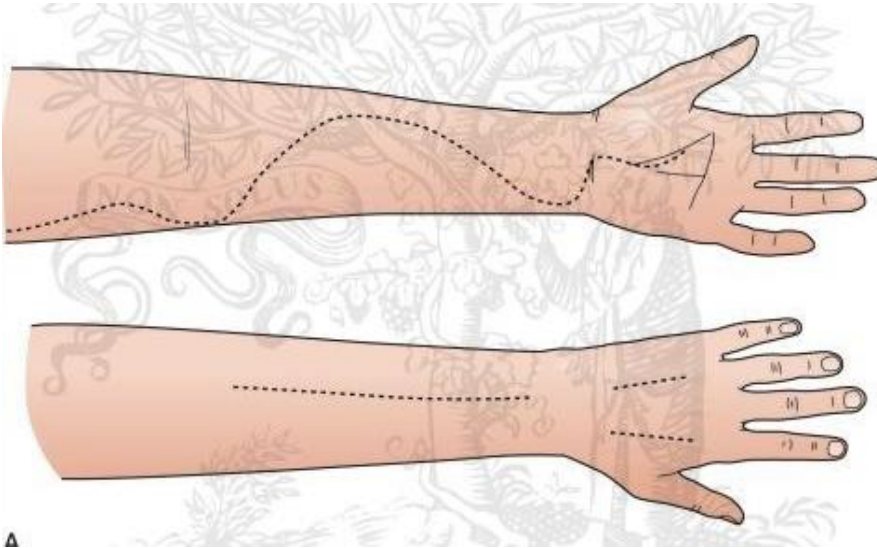
CLOSED TRAUMA (CONTUSIONS)

The contusions are the result of a blunt object action or of an over solicitation of joints, ligaments or tendons.

The edema (swelling) is always present in this situations and it has to be treated by raised position of the hand (postural treatment) in „functional position”.

When the edema is very high, the pressure in closed osteo-fascial compartments of the hand – **compartment syndrome** - can compromise the nutrition of the muscles and nerves and need immediate treatment, by surgical incisions including the fascia. The main symptom in compartment syndrome is pain and when visible signs of ischemia occur in the distal segment it can be too late, because muscles and nerves can be injured irreversible.

The incision can be sutured after 5-10 days.

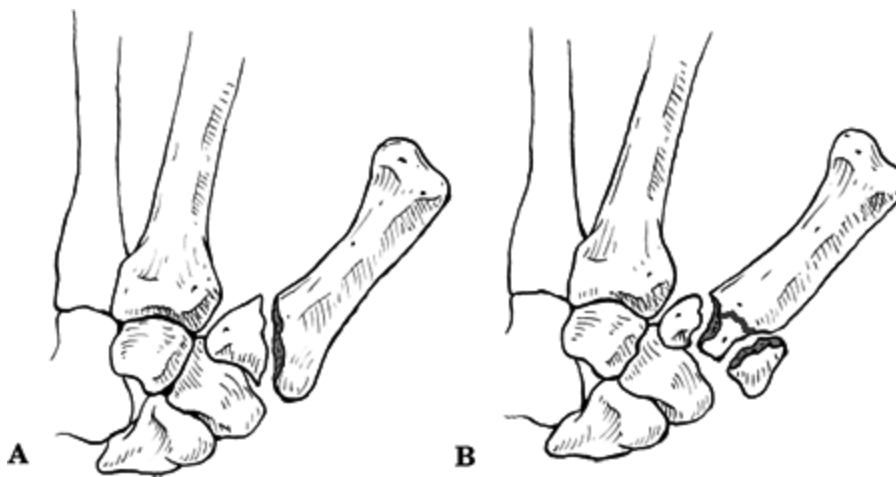


5. Fasciotomy

FRACTURES

Closed fractures determine deformation of the hand because of edema and mobilization of the bone fragments. It always occur ecchymosis, pain, abnormal mobilization of the bone fragments, cracments (specific noises) in fracture region. The diagnosis will be certified by radiological investigation.

The tretment needs a stable reduction of the fracture for 6-8 weeks in functional position. It can be done by closed reduction of the fracture and immobilization. When the reduction is impossible or when there is a comminutive fracture (more than 2 fragments) we need an open bone fixation (osteosynthesis) by K-wire, cerclaje, screw, plate and screws or external fixation.

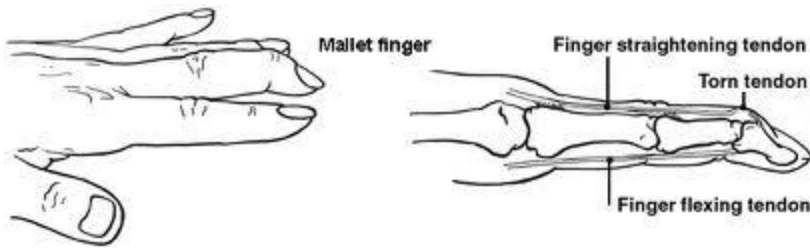


6. a. Bennet fracture

b. Rolando fracture

CLOSED TENDON LESIONS

The most common closed tendon lesions are avulsion of the bone insertion of the flexor or extensor tendons. For the extensor tendon dezinsertion (hammer finger) it may be necessary only immobilization in extension of the distal phalanx for 6-8 weeks. For the flexor tendon dezinsertion the surgical reinsertion of the tendon in the distal phalanx is necessary.



7. Mallet finger

CLOSED LIGAMENT LESIONS

Closed ligament lesions determine joint dislocation (luxation). This kind of lesions occur especially in the PIP (proximal interphalangeal) joints. If closed luxation reduction is stable we splint the joint for 2-3 weeks. If it is not stable or the collateral ligaments are injured the surgical luxation reduction with ligaments suture is necessary.

OPEN TRAUMA (WOUNDS)

MINOR WOUNDS

A big number of the patients with hand trauma have minor wounds. If no vessels, nerves or tendon lesions are identify by clinical examination the wound can be sutured in the emergency room by local anesthesia.

The wound is carefully washed with saline and antiseptic or antibiotic solutions. The skin edges are minimally excised and than sutured after wound exploration.

Nail bed wounds can determine under nail hematoma. It can be treated by hematoma evacuation performing a hole in the nail or it can need nail removal, nail bed suture with 6-0 resorbable suture and reposition o the nail. Distal phalanx fractures can be present and they will be splinted.

VESSELS WOUNDS

Vessels wounds can compromise vascularisation in the distal segment of the hand. In these cases the vessels will be sutured using magnification (loupes or surgical microscope) and microsurgical technique.

If the vascularisation of the distal segment is not compromise the vessels edges will be ligated.

NERVES WOUNDS

Nerves wounds need careful treatment because they can determine major hand malfunction even if other structures lesions well treated.

Nerves suture are performed only using magnification and microsurgical technique. Primary nerve repair (first 24 hours after the trauma) has better functional results. Secondary nerve repair (after 3 weeks) is more difficult surgery because of the scar and may need nerve grafting in case of nerve edges retraction or important neuroma, using less important sensitive nerves (sural nerve) as graft.

Usually the hand will be splinted for 3 weeks after nerve repair. Nerve will grow from the lesion level by 1mm per day, so the full recovery may take long time. In this period the patient needs therapy to preserve joints, muscles and tendons function.

MUSCLES AND TENDONS WOUNDS

Muscles wounds need to be sutured using resorbable stitches for muscle body and nonresorbable for fascia. Splinting in functional position will be maintained for 3 weeks.

Extensor tendons wounds need tendon suture using nonresorbable suture and splinting in extension for 2-3 weeks.

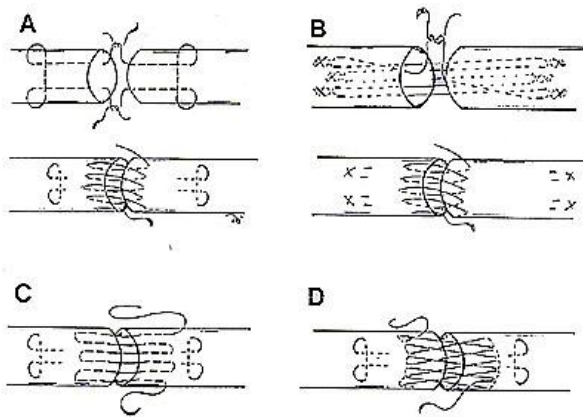
Flexor tendons wounds also need to tendon suture. Usually when both the FTP and FTS are sectioned they both need to be sutured. The FTP provides movement in PIP and DIP joint so in

old patients or complicated cases only the FTP is sutured to avoid tenodesis (FTP with FTS adhesion by scar tissue) and to obtain a better functional result. Flexor tendons are sutured with nonresorbable suture.

Splinting in functional position is always used after tendons repair for 3 weeks, but passive and controlled active movements are performed to avoid joint stiffness and adherence of the tendon with the scar tissue around. If 3 months therapy after flexor tendons repair has no results, surgical tenolysis may be performed.



8. Verdans zones of injury



9. Types of tenorrhaphy

BONES AND JOINTS WOUNDS

Open fractures are similar treated with closed fractures and they need reduction, immobilization for 6-8 weeks. Bone fixation will be performed using Kirschner wire (K-wire), cerclage, screws, plate, external fixation or different combinations (usually K-wire and cerclage), depending on the type and comminution degree of the fracture.

Open joint lesions need as better as possible joint reconstruction, preserving articular surfaces. The ligaments will be also sutured to avoid secondary luxations. Splinting will be necessary for 6 weeks. If the articular surfaces can not be preserved it will be performed arthrodesis in functional position, which will preserve some function of the finger.

AMPUTATION

The amputation is one of the most severe traumas. Surgery is replantation in complete amputations and revascularization in incomplete amputations and needs to preserve length, mobility and sensation of the amputated segment.

Indications for replantation and revascularization are:

- thumb amputations
- multiple finger amputations

- hand level amputations
- wrist level amputations
- forearm level amputations
- distal third arm amputations
- almost any level amputations in children

Replantation and revascularisation is contraindicated in

- crush or severe burns of the amputated segment
- multiple levels amputations
- severe associated organ lesions
- psychiatric patients
- single finger amputations
- not proper preservation of the amputated segment

First aid in these cases is very important. It will consist in bandageing of the stump and preservation of the amputated segment in ice solution, but not in contact with ice or liquid to avoid frost bites or maceration. No ligation of the vessels will be performed. Bleeding can be controlled by using the tourniquet for maximum 1.5-2h. It will be organized rapid transport to the specialized replantation unit and the replantation team will be announced by phone call. Blood tests can be performed. Radiological investigations of the stump and amputated segment have to be performed. Two surgical teams are needed, one for the stump and the other one for the amputated segment(s).

After the patient is anesthetized the surgical steps are:

- lavage with saline or antiseptic solutions and debridement of the wounds, taking out foreign bodies and excising all devitalized tissue
- dissection of the bone, tendons/muscles vessels and nerves

- bone fixation after shortening the bone with 1-3cm (to have the possibility of direct suture of the vessels, nerves, tendons/muscles)
- tendons/muscles suture
- vessels suture (by microvascular technique)
- nerves suture (by microvascular technique)
- skin suture to cover the elements reconstructed before
- no pressure bandageing

Postop. medication will include antibiotics, anti-inflammatory drugs, analgesic drugs, antisludging treatment, and sedative drugs for 5-7 days. Bandage changing will be performed as rare as possible.

Rehabilitation program after surgery will start as soon as patient's general condition will permit (3-4 days after surgery) and can provide good functional recovery.

When replantation is not possible, the stump will be closed, preserving as much length as possible.